

Hand Tumors: Lumps and Bumps

What are Hand Tumors?

Any abnormal lump or bump is considered a tumor. A tumor can also be referred to as a "mass". The term "tumor" does not necessarily mean it is malignant or it is a cancer. In fact, the vast majority of hand tumors are benign or non-cancerous. Any lump or bump in your hand is a tumor regardless of what causes it.

Hand tumors can occur on the skin, like a mole or a wart, or can occur underneath the skin in the soft tissue or even the bone. Because there are so many tissue types in the hand (e.g. skin, tendon, fat, ligaments, bone, etc) there are many types of tumors that can occur. However, only a few of them are seen commonly.

What types of Hand Tumors are there?

The most common tumor in the hand and wrist is a **ganglion cyst**. These are benign sacs of gelatinous fluid that form off of a joint or tendon sheath. They are seen frequently in the wrist but can also occur around finger joints. They form when a portion of the joint capsule or tendon sheath starts ballooning out and becomes filled with the fluid that lubricates the joint or tendon. The diagnosis and treatment options are discussed in more detail in another brochure and in a separate section on the ASSH web-site.

The 2nd most common hand tumor is a **giant cell tumor of tendon sheath**. Unlike the fluid-filled ganglion cyst, these tumors are solid masses. They can occur anywhere there is a nearby tendon sheath. They are benign, slow-growing masses that spread through the soft tissue underneath the skin (see **Figure 1**). Some believe that they may be caused by trauma that stimulates the tendon sheath to start growing abnormally. They are not cancer.

Another common tumor is an **epidermal inclusion cyst** (see **Figure 2**). It is also benign and forms just underneath the skin, originating from the undersurface of the skin where there may have been a cut or puncture. Skin cells normally secrete a protective waxy substance called keratin. They also undergo a cycle in which surface skin cells die and slough off into the environment. When skin cells get trapped under the surface, they continue to make keratin and continue to reproduce and slough. The keratin and dead skin cells get trapped underneath the skin and start forming the cyst. The cyst grows as more keratin is produced and more skin cells die. Ultimately, you get a fibrous sac filled with a cheesy substance that is attached to the undersurface of the skin from where it arose.

There are other less common types of tumors seen in the hand. They include lipomas (fatty tumors), neuromas, nerve sheath tumors, fibromas, and glomus tumors among others (see **Figure 3**). They are practically all benign. Bone spurs can form, from arthritis or trauma, which feel like hard tumors. Foreign bodies, like a splinter, can also cause reactions that form lumps or bumps in the hand (see **Figure 4**).

What about Hand Cancer?

Whenever patients discover a lump or bump in their hand, one of their first concerns is whether or not they have cancer. Fortunately, cancer in the hand is very rare. The most common primary hand malignancies are skin cancers like squamous cell carcinoma, basal cell carcinoma, or melanoma. Other cancers are very rare but include sarcomas of the soft tissue or bone. It is also possible for cancer to spread to the hand from somewhere else in the body, like lung or breast cancer. This would represent metastatic cancer. With any cancer in the extremity, some type of tissue biopsy is usually required to make a definitive diagnosis.

Evaluation and Treatment

A careful history and physical exam performed by a hand surgeon can narrow down the possibilities as to the type of tumor a patient has. X-rays might be taken if there is concern about bony involvement or to evaluate the soft tissue. Recommendations for treatment are based on the experience of the hand surgeon and preferences of the patient.

Typically, definitive treatment with the lowest recurrence rate involves **surgical excision of the tumor**. Excising the tumor also allows a pathologist to analyze it and determine exactly what type it is with reasonable certainty. Surgery can frequently be done on an outpatient basis and may not require a general anesthetic. Risks and benefits should be discussed with the surgeon. Most tumors can be cured with surgery.

If the doctor thinks the tumor is a ganglion cyst, then trying to aspirate or inject the cyst may be an option if the patient does not want surgery, though recurrence is fairly common. Needle biopsy or incisional biopsy may be considered for a solid tumor if the surgeon wants to get a tissue diagnosis before recommending definitive treatment.

Some patients may choose to do nothing and simply live with the tumor once they learn that it is probably benign. Typically, however, tumors get bigger with time and can become more of a nuisance. Patients should also consider the risks, benefits, and consequences if choosing not to have surgery. Hand surgeons can provide information and advice to allow patients to make the best decisions regarding their treatment plans.

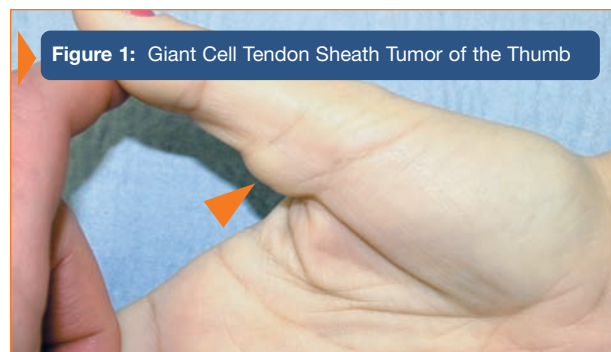

Figure 1: Giant Cell Tendon Sheath Tumor of the Thumb

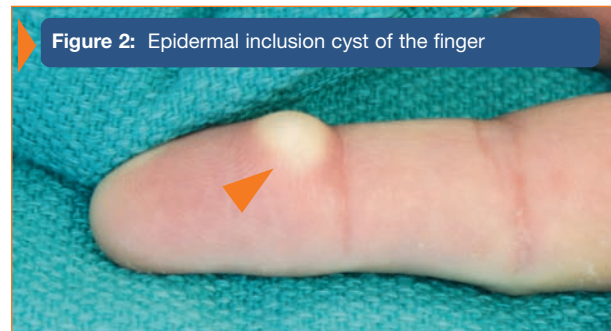

Figure 2: Epidermal inclusion cyst of the finger

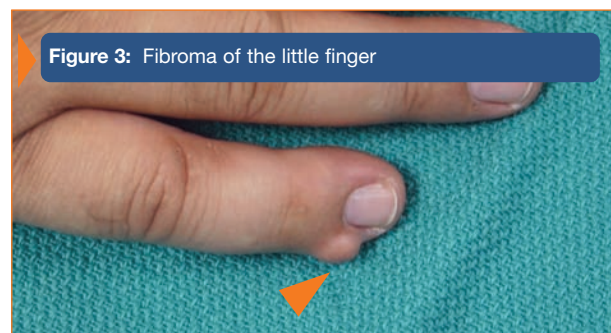


Figure 3: Fibroma of the little finger

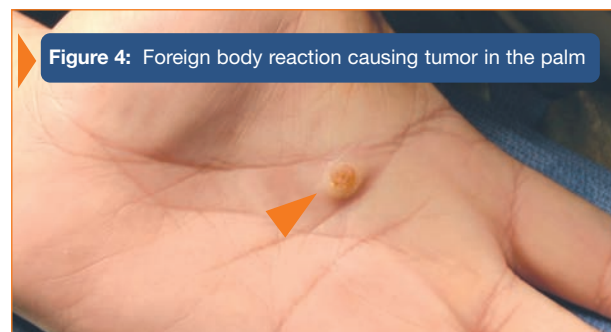


Figure 4: Foreign body reaction causing tumor in the palm